

Delayed Presentation of Rectum and Sigmoid Colon Injury Following a Blunt Abdominal Trauma

M. Khader Ali Khan¹, Naheeda Begum Shaik²

Author's Affiliation:

¹Junior Consultant, Department of Emergency Medicine, People Tree Hospital, Yeshwanthapur, Bangalore, Karnataka 560022, India.
²Junior Consultant, Department of Emergency Medicine, Columbia Asia Hospital, Sarjapur Road, Bangalore, Karnataka 560102, India.

Corresponding Author:

Naheeda Begum Shaik, Junior Consultant, Department of Emergency Medicine, Columbia Asia Hospital, Sarjapur Road, Bangalore, Karnataka 560102, India.

E-mail: dr.naheeda.s@gmail.com

Received on 16.01.2019,

Accepted on 06.03.2019

Abstract

Introduction: The delayed presentation of Rectal Injuries / perforations following a blunt trauma to the abdomen adds significantly to the morbidity, mortality and increased hospital stay and pain to the patient. **Case Report:** A 42 yr old male patient has been admitted in the emergency department with history of blunt abdominal trauma after getting struck between the steering wheel and the drivers seat for a long time in a RTA. His vitals were normal. He was discharged home after the CT scan (both plain and contrast) showed no organ injury as reported by the radiologist. Later after 12 hrs he was re-admitted in the emergency with severe abdominal pain and guarding. X-ray erect abdomen showed air under diaphragm and it was later diagnosed as rectal perforation in CT and also taken to OT for surgical repair. **Conclusion:** Rectal injury or perforation following a blunt abdominal trauma is such a trivial thing in the beginning to find even on CT scans. It takes time to evolve into fully blown acute abdomen with peritonitis. So there is a need for re-evaluation in all patients of blunt abdominal trauma who appears to be normal on investigations out of proportion to the injury that they sustained.

Keywords: Rectal perforation; Blunt abdominal trauma; CT scan.

Introduction

The rare occurrence of colonic injuries following blunt abdominal trauma and lack of definitive diagnostic modality can lead to delay in diagnosis and treatment in the initial stage which can ultimately result in high morbidity and mortality.

Case Presentation

A 42 year old man involved in a Motor Vehicle Accident (MVA) had been brought to our emergency department.

Mechanism: patient was driving lorry and had head on collision with another lorry and he was stuck between the steering wheel and the driver's seat.

Clinical Examination

Primary survey and vital signs: ABCDE - Normal. BP - 152/102 mm Hg, Pulse - 94 bpm.

Secondary survey: tenderness in left iliac fossa.

Initial ER Investigations:

E Fast - Negative.

Erect Chest X Ray: Normal Study (Fig. 1).

The initial leucocyte count was 12040.

CECT Abdomen and pelvis: No solid organ injury or free fluid in the abdomen (Fig. 2 and 3).

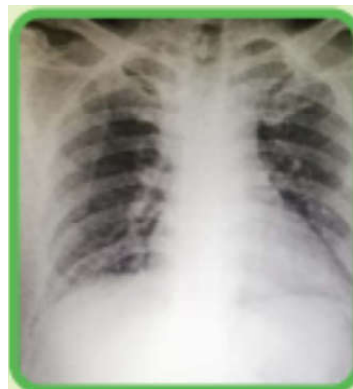

Fig. 1: Initial X ray

Table 1: CBC

Hemoglobin	13.8	g/dl
Total count	12040	Cells/mm ²
Neutrophil	86.0	%
Lymphocyte	9.2	%
Platelet count	199000	Cells/mm ²
PCV	39.7	%

Course in the hospital:

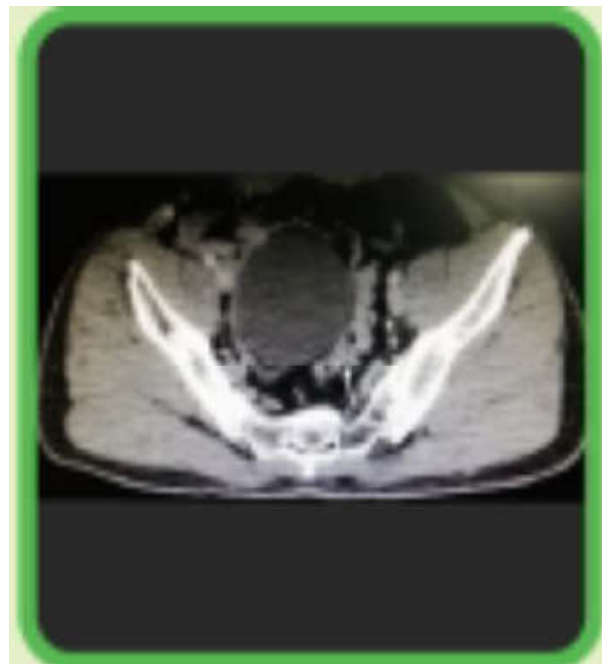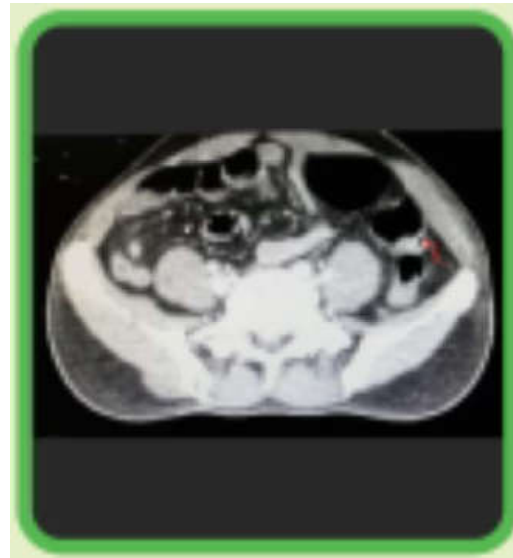
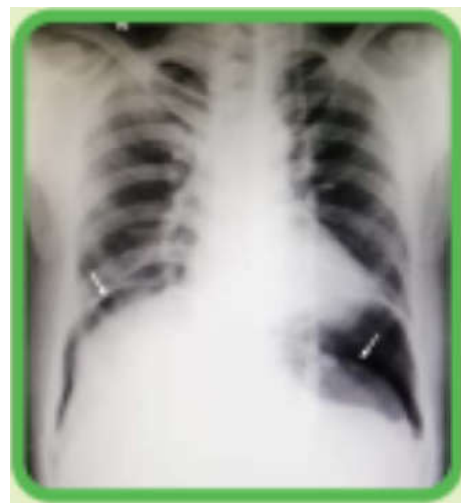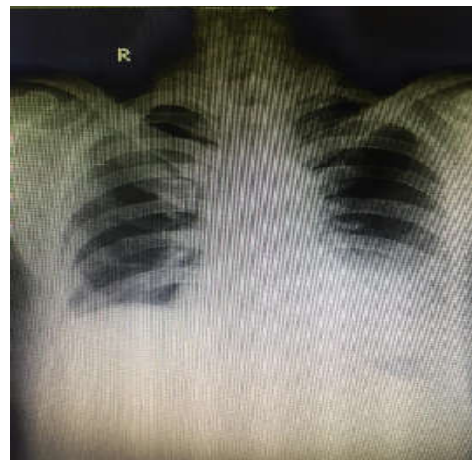Surgical consultation was obtained and patient was admitted to observation unit. During initial 6 hours of observation patient remained vitally stable with no signs and symptoms suggestive of intra abdominal injury. The patient was discharged on request after detail advice regarding warning signs and symptoms and to return SOS.

Return To ER:

6 hrs after the discharge patient returned to the emergency department c/o severe pain abdomen and abdominal distension. On examination abdomen was distended with diffuse tenderness and guarding. Repeat chest X ray was obtained (Fig. 4).

Management:

Immediately taken to OR for explorative laparotomy. Primary closure of sigmoid colon perforation and loop ileostomy was done and he was discharged after complete recovery a week later (Fig. 5).

**Fig. 2:** Initial CT scan white arrow - Sigmoid colon**Fig. 3:** Initial CT scan Red arrow - Descending colon**Fig. 4** Chest X ray after re-admission**Fig. 5:** X ray at the time of discharge

Discussuion

Traumatic colonic injuries

1. Mechanism – Penetrating abdominal injury is much more common as compared to blunt abdominal injury (with incidence as low as 1.1% and most common reason being motor vehicle accident) [1,2].
2. Anatomy – Transverse colon is most vulnerable and sigmoid colon is least vulnerable for injuries [1].
3. Imaging – No imaging modality has 100% sensitivity and specificity for diagnosing colonic injuries in initial stages. Diagnostic value of contrast CT scan in initial stages remains controversial [1].
4. Diagnosis – Dangerous mechanism of injury + Serial physical examination + Serial imaging if required + High index of suspicion.
5. Prognosis – prognosis depends upon the time between arrival to the emergency department and surgery. Rate of complications is higher if duration is more than 24 hrs [2].

Conclusion

Colonic injury secondary to blunt abdominal trauma is rare and management has the potential to get delayed due to difficulties in establishing a conclusive diagnosis. Clinicians should maintain a high index of suspicion when evaluating patients

with dangerous mechanism of injury and initial normal ER examination. Patients should be examined repeatedly and should undergo serial imaging if indicated to reach definitive diagnosis.

References

1. Singh M, Dalal S, Amardeep, Sattibabu V. Delayed Presentation of an isolated Sigmoid Colon Injury Following Blunt Abdominal Trauma : A Case Report & Review of Literature. OGH Reports. 2017;6(2):75-6.
2. Ertugrul et al. : Delayed presentation of a sigmoid colon injury following a blunt abdominal trauma : A case report. Journal of Medical Case Reports. 2012 6:247.
3. Zheng YX, Chen L, Tao SF, Song P, Xu SM. Diagnosis and management of colonic injuries following blunt trauma. World J Gastroenterol. 2007;13(4):633-36.
4. Injury to Colon and Rectum. Trauma.org. [Http://www.trauma.org/index.php/main/article/403/print](http://www.trauma.org/index.php/main/article/403/print).
5. F. Ceci, M. Picchio, S. Corelli, P. Gammardella, M. Santilli, F. Stagnitti, A. Rebonato. Sigmoid colon injury due to blunt abdominal trauma. A case report. G Chir. 2006;27(6/7):259-261.
6. Nurullah Damburaci, Baris Sevinc, Omer Karahan. Traumatic perforation of sigmoid colon. A case report. Turk J Colorectal Dis. 2017;27:158-60.
7. JFNolan. Delayed presentation of rectal perforation. Journal of the Royal Society of Medicine. 1990 Nov;83:744-45.

Red Flower Publication Pvt. Ltd.

CAPTURE YOUR MARKET

For advertising in this journal

Please contact:

International print and online display advertising sales

Advertisement Manager

Phone: 91-11-22756995, 22754205, 45796900, Cell: +91-9821671871

E-mail: sales@rfppl.co.in

Recruitment and Classified Advertising

Advertisement Manager

Phone: 91-11-22756995, 22754205, 45796900, Cell: +91-9821671871

E-mail: sales@rfppl.co.in